
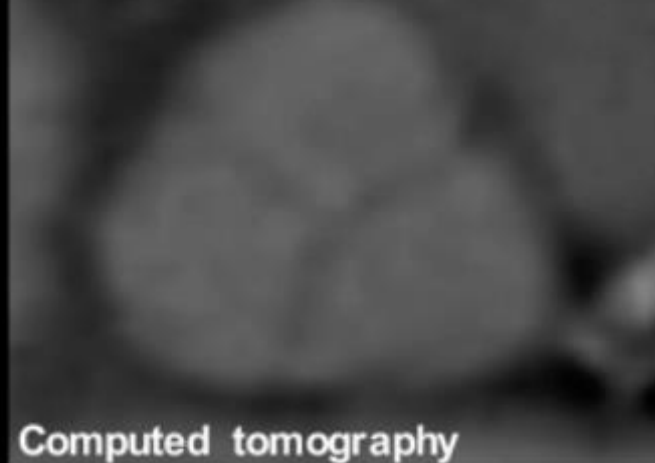


Participant with a low Lp(a)
level (7.8 nmol/L)

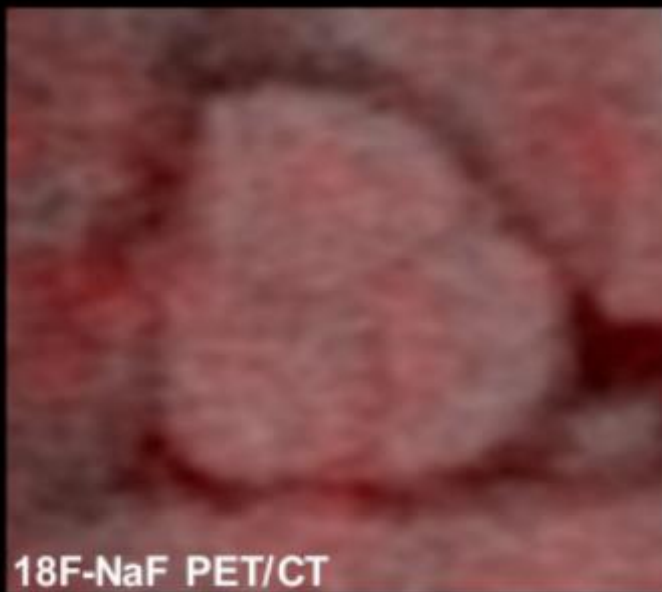


Computed tomography

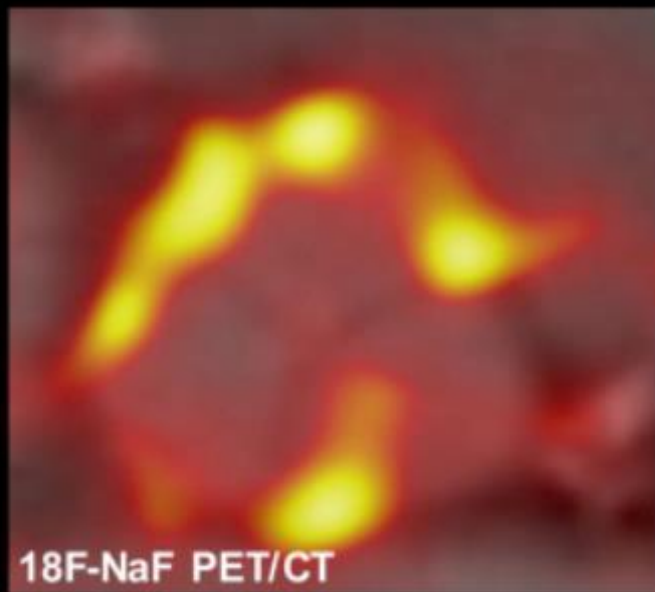
Participant with a high Lp(a)
level (256.9 nmol/L)



Computed tomography



¹⁸F-NaF PET/CT



¹⁸F-NaF PET/CT

Representative image of aortic valve microcalcification in a patient with a low Lp(a) level (CT at the top left and PET/CT at the bottom left) and a patient with a high Lp(a) level (CT at the top right and PET/CT at the bottom right).